

BULLET FRAGMENTS IN DEER REMAINS: IMPLICATIONS FOR LEAD EXPOSURE IN SCAVENGERS

GRAINGER HUNT¹, WILLIAM BURNHAM¹, CHRIS PARISH¹, KURT BURNHAM¹,
BRIAN MUTCH¹, AND J. LINDSAY OAKS²

¹*The Peregrine Fund, 5668 West Flying Hawk Lane, Boise, ID 83709, USA.*
E-mail: grainger@peregrinefund.org

²*Department of Veterinary Microbiology and Pathology, Washington State University,
Pullman, WA 99164-7040, USA.*

ABSTRACT.—Bullet fragments in rifle-killed deer carrion have been implicated as agents of lead intoxication and death in Bald Eagles (*Haliaeetus leucocephalus*), Golden Eagles (*Aquila chrysaetos*), California Condors (*Gymnogyps californianus*), and other avian scavengers. Deer offal piles are present and available to scavengers in autumn, and the degree of exposure depends upon incidence, abundance, and distribution of fragments per offal pile and carcass lost to wounding. In radiographs of selected portions of the remains of 38 deer supplied by cooperating, licensed hunters in 2002–2004, we found metal fragments broadly distributed along wound channels. Ninety-four percent of samples of deer killed with lead-based bullets contained fragments, and 90% of 20 offal piles showed fragments: 5 with 0–9 fragments, 5 with 10–100, 5 with 100–199, and 5 showing >200 fragments. In contrast, we counted a total of only six fragments in 4 whole deer killed with copper expanding bullets. These findings suggest a high potential for scavenger exposure to lead. *Reproduced with permission from the Wildlife Society Bulletin 34(1):167-170, 2006.*

HUNT, G., W. BURNHAM, C. PARISH, K. BURNHAM, B. MUTCH, AND J. L. OAKS. 2009. Bullet fragments in deer remains: Implications for lead exposure in scavengers. *In* R. T. Watson, M. Fuller, M. Pokras, and W. G. Hunt (Eds.). *Ingestion of Lead from Spent Ammunition: Implications for Wildlife and Humans*. The Peregrine Fund, Boise, Idaho, USA. DOI 10.4080/ilsa.2009.0123

Key words: Bullet fragmentation, lead, lead poisoning, raptors, scavengers.

AVIAN PREDATORS AND SCAVENGERS are susceptible to lead poisoning when they ingest pellets or fragments in the tissues of animals wounded or killed by lead-based bullets (Franson 1996, Locke and Thomas 1996, Wayland and Bollinger 1999). Toxic effects of ingested lead include neural degeneration, modification of kidney structure and bone, and inhibition of blood formation and nerve transmission (Eisler 1988). Shotgun pellets experimentally fed to five Bald Eagles (*Haliaeetus leucocephalus*) killed four of them, and severe clinical signs prompted euthanization of the fifth (Hoffman

et al. 1981, Pattee et al. 1981). Residual weights of recovered pellets showed that the five eagles dissolved (mobilized) totals of 19, 38, 42, 129, and 184 mg of lead, each less in mass than a single #4 pellet of 209 mg.

Harmata and Restani (1995) found lead in the blood of 97% of 37 Bald Eagles and 85% of 86 Golden Eagles (*Aquila chrysaetos*) captured as spring migrants in Montana during 1985–1993. Pattee et al. (1990) reported that 36% of 162 free-ranging Golden Eagles captured during 1985–86 in south-

ern California had been exposed to lead, and 9% had blood lead levels >0.6 ppm. Six of nine dead or moribund eagles (*Haliaeetus* spp.) in Japan died of lead poisoning; five had lead bullet fragments in their stomachs, and evidence implicated hunter-killed deer as the primary vector (Iwata et al. 2000). Lead ingestion was a principal cause of recorded death in wild California Condors (*Gymnogyps californianus*) prior to the mid-1980s when the population was brought into captivity (Wiemeyer et al. 1988), and in subsequently reintroduced, captive-bred condors tracked with radio-telemetry in Arizona (Cade et al. 2004). Kramer and Redig (1997) found a reduction in blood lead concentrations in Bald and Golden Eagles after a 1987 ban on lead shot for waterfowl hunting in Minnesota and Wisconsin; however, they found no change in prevalence of lead poisoning, a finding the authors attributed in part to offal piles from hunter-killed deer.

The availability of ungulate offal piles can be high in some regions. For example, the ten-year mean (1992–2001) of 676,739 White-tailed Deer (*Odocoileus virginianus*) annually harvested by rifle hunters in Wisconsin would have produced an average density of about five offal piles per km² for the area of the entire state (Dhuey 2004). An unknown number of additional whole carcasses lost to wounding is present in the landscape during and after hunting seasons, possibly on the order of 10% or more (Nixon et al. 2001). The extent to which avian scavengers encounter lead in deer carrion is therefore not so much a question of carrion availability, but rather one of lead incidence, abundance, and distribution per offal pile or carcass. Our examination of these three factors using radiographic data strengthens the body of evidence that deer killed by rifle bullets are a potentially important pathway of lead contamination to scavenger food webs.

METHODS

We obtained whole or partial remains of 38 deer (*Odocoileus virginianus* and *O. hemionus*) killed with standard, center-fire, breach-loading rifles by participating, licensed hunters engaged in normal hunting practices in Wyoming and California during 2002–2004. Thirty-four (89%) of the deer were

killed by single shots to the thorax as determined by carcass examination and hunter interviews. The samples consisted of 15 offal piles discarded by hunters in the field, 10 deer carcasses in which tissues and viscera anterior to the diaphragm were left in place (abdominal viscera removed), four eviscerated carcasses, and nine whole deer carcasses; the latter were eviscerated on polyethylene sheets to sequester offal for radiography.

Hunters chose rifles, bullets, and bullet weights. Hunters used seven standard deer rifle calibers, and the mean weight of 37 bullets was 145 grains (SD = 18, range 100–180). Thirty-four were standard copper-jacketed, lead core bullets, and four were monolithic copper expanding “X-bullets.” Seventeen of the former were of lead-tipped configuration (five brands), 12 were polymer-tipped (five brands), two were hollow points (one brand), and three were of unrecorded structure. Shot distances varied from 37 to >200 m (mean of 12 ranged distances = 158 m, SD = 77).

Local veterinarians radiographed areas of bullet transition of all carcasses and offal dorsoventrally and laterally; and adjusted exposures to maximize contrast (e.g., 56–70 kvp, 100 mAS, 0.3 sec). We placed a 2.5-cm grid transparency on selected radiographs, and using a hand (reading) lens for clarity, we counted all unambiguous metal fragments (opaque to radiation) in each cell and summed the counts. We verified the presence of metal particles in one sample by dissection. We estimated the width of the fragment arrays (excluding outliers) in five samples by extrapolation from the width of a 9-mm-diameter carbon-fiber tube inserted through the wound channel and aligned perpendicular to the x-ray beam. We did not attempt to distinguish between copper and lead in fragment counts. Copper, which is less frangible than lead, accounted for 30% of the mass in one standard (.308 caliber, 150-grain) hunting bullet we analyzed.

RESULTS

Most radiographs showed a profusion of small (<2 mm) metal fragments broadly distributed along wound channels. In deer killed by lead-based bullets, radiographs showed fragments in 18 of 20 offal piles (range = 2–521 fragments, mean = 160,

SD = 157). Five showed 0–9 fragments, five had 10–99, five had 100–199, and five showed >200 fragments. We counted 416–783 fragments (mean = 551, SD = 139) in the five whole deer carcasses (Figure 1), and 25–472 (mean = 213, SD = 172) in 10 carcasses containing thoracic organs but no abdominal viscera. Nine eviscerated carcasses showed fragments (range = 38–544, mean = 181, SD = 153). Fragment clusters in five samples radiated as far as 15 cm from wound channels; the average of 30 measurements of the most far-reaching clusters in 11 radiographs was 7 cm (SD = 3). Magnification of one sample of excised tissue showed that fragments ranged in size from a few of >5 mm to tiny ones beyond the limit of unaided vision, estimated to be about 0.5-mm. Copper bullets resisted fragmentation: we counted a total of only six fragments in four (whole) deer killed with these bullets, and only one in the offal piles (Table 1).

DISCUSSION

The surprisingly high incidence of metal retention in carcasses as a result of fragmentation, and the density and distribution of fragments within them, suggest a high potential exposure of scavengers to lead. All whole or eviscerated deer killed with lead-based bullets contained fragments, 74% of them showing >100 visible fragments. The high proportion (90%) of offal piles containing fragments is not surprising, given that gut piles contain the thoracic organs normally targeted by hunters. The minuteness of many fragments may explain why lead is often unseen in radiographs of lead-poisoned birds (Kramer and Redig 1977); small fragments may be overlooked or completely digested. Ingestion of very small particles of lead would explain the accumulation of sublethal levels in the blood of Golden Eagles during the hunting season (Wayland and Bollinger 1999).

Experiments on projectile toxicity have focused on shotgun pellets (Hoffman et al. 1981), and extrapolations from those experiments may underestimate the effects of rifle bullet fragments under natural conditions. The toxicity of ingested bullet fragments that are irregularly shaped must be greater than those of shotgun pellets of comparable mass because pellets, being spherical, have less surface

area exposed to stomach acids. Moreover, the apparent high densities and small sizes of bullet particles likely contribute to their multiple ingestion by individual scavengers, and surface area within an aggregate of ingested particles would be greater than that of spherical pellets or intact bullets of comparable mass.

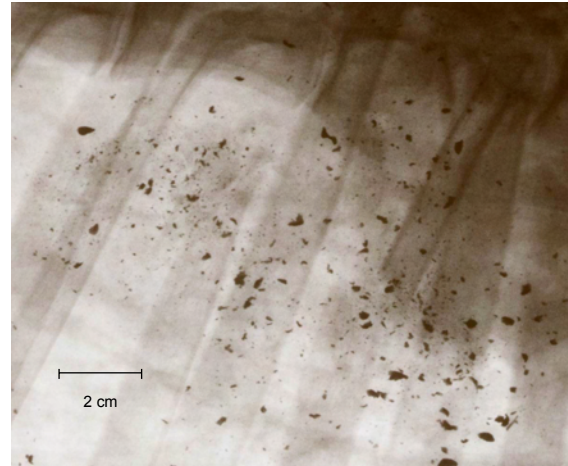


Figure 1. Lateral-view radiograph of the mid-thorax of an adult female White-tailed Deer killed by a standard copper-jacketed, lead-core, soft-point hunting bullet in northern Wyoming in 2004. The fragment array surrounding the bullet path was approximately 12 cm in diameter, excluding outliers.

Table 1. Metal fragments counted in radiographs of the remains of nine deer in which whole carcasses were available for study. Lead-based bullets (one brand) were of standard, copper-jacketed, soft point (lead-tipped) configuration. Expanding copper bullets (one brand) contained no lead. The deer were killed in northern Wyoming in fall 2004.

	<i>Offal Pile</i>	<i>Eviscerated Carcass</i>
Lead-based bullets	218	236
	450	214
	521	95
	67	224
	161	544
Copper bullets	0	0
	0	2
	0	0
	1	2

Based on these findings, we recommend further study on the frangibility of the various kinds of rifle bullets and continued use of carcass radiography to determine the incidence of bullet fragments in carcasses. Meanwhile, deer gut piles left in the field and whole deer carcasses lost to wounding should be considered as potentially poisonous to scavengers. Evidence of the perniciousness of ingested lead (Pattee et al. 1981) as manifested, for example, in the minute absorbed amounts that killed eagles under experimental conditions, give incentive for change to safer alternatives. Copper is less toxic than lead and less frangible. In reviewing a wide range of ballistics literature, we have encountered numerous test results and accounts supporting the efficacy of copper expanding bullets in hunting (see McMurphy 2002).

ACKNOWLEDGMENTS

We thank P. Widener, R. Berry, P. Pelissier, M. Murray, and the Mountain View Veterinary Hospital, Sheridan, Wyoming for special help with this project. Hunters providing deer for this study included P. Jenny, B. Widener, L. Widener, P. Widener, P. Hunt, and three of the authors. Additional assistance was provided by A. Brubaker, T. Cade, K. Evans, J. Fry, M. Gilbert, W. Heinrich, R. Jackman, S. Marrug, A. Matz, R. Mutch, B. Oakleaf, T. Hunt, R. Tucker (Washington State University), the Arizona Game and Fish Department, the Wyoming Game and Fish Department, and The Peregrine Fund Research Library. We thank M. Goldstein, R. Risebrough, V. Thomas, and two anonymous reviewers for helpful comments on the manuscript. Financial support was provided by The Peregrine Fund.

LITERATURE CITED

- CADE, T. J., S. A. H. OSBORN, W. G. HUNT, AND C. P. WOODS. 2004. Commentary on released California Condors in Arizona. Pages 11–25 in R. D. Chancellor and B. U. Meyburg (Eds.). *Raptors Worldwide*. World Working Group on Birds of Prey and Owls, Berlin and MME/Birdlife Hungary, Budapest, Hungary.
- DHUEY, B. 2004. Wisconsin Big Game Hunting Summary. Wisconsin Department of Natural Resources Report Pub-WM-284 2004.
- EISLER, R. 1988. Lead hazards to fish, wildlife, and invertebrates: a synoptic review. United States Fish and Wildlife Service, Biological Report 85 (1.14), Patuxent Wildlife Research Center, Laurel, Maryland, USA.
- FRANSON, J. C. 1996. Interpretation of tissue lead residues in birds other than waterfowl. Pages 265–279 in W. N. Beyer, G. H. Heinz, and A. W. Redmon-Norwood (Eds.). *Environmental Contaminants in Wildlife: Interpreting Tissue Concentrations*. CRC Press, Boca Raton, Florida, USA.
- HARMATA, A. R., AND M. RESTANI. 1995. Environmental contaminants and cholinesterase in blood of vernal migrant bald and golden eagles in Montana. *Intermountain Journal of Sciences* 1:1–15.
- HOFFMAN, D. J., O. H. PATTEE, S. N. WIE-MEYER, AND B. MULHERN. 1981. Effects of lead shot ingestion on g-aminolevulinic acid dehydratase activity, hemoglobin concentration, and serum chemistry in Bald Eagles. *Journal of Wildlife Distribution* 17: 423–431.
- IWATA, H., M. WATANABE, E. Y. KIM, R. GOTOH, G. YASUNAGA, S. TANABE, Y. MASUDA, AND S. FUJITA. 2000. Contamination by chlorinated hydrocarbons and lead in Steller's Sea Eagle and White-tailed Sea Eagle from Hokkaido, Japan. Pages 91–106 in M. Ueta and M. J. McGrady (Eds.). *First symposium on Steller's and White-tailed Sea Eagles in East Asia*. Wild Bird Society of Japan, Tokyo, Japan.

- KENDALL, R. J., T. E. LACHER, JR., C. BUNCK, B. DANIEL, C. DRIVER, C. E. GRUE, F. LEIGHTON, W. STANSLEY, P. G. WATANABE, AND M. WHITWORTH. 1996. An ecological risk assessment of lead shot exposure in non-waterfowl avian species: upland game birds and raptors. *Environmental Toxicology and Chemistry* 15:4-20.
- KRAMER, J. L., AND P. T. REDIG. 1997. Sixteen years of lead poisoning in eagles, 1980-95: An epizootiologic view. *Journal of Raptor Research* 31:327-332.
- LOCKE, L. N., AND N. J. THOMAS. 1996. Lead poisoning of waterfowl and raptors. Pages 108-117 in A. Fairbrother, L. N. Locke, and G. L. Huff (Eds.). *Noninfectious Diseases of Wildlife* 2nd ed. Iowa State University Press, Ames, Iowa, USA.
- MCMURCHY, I. 2003. Barnes XLC bullets. *American Hunter* 31(1):70-71.
- NIXON, C. M., L. P. HANSEN, P. A. BREWER, J. E. CHELSVIG, T. L. ESKER, D. ETTER, J. B. SULLIVAN, R. G. KOERKENMEIER, AND P. C. MANKIN. 2001. Survival of White-tailed Deer in intensively farmed areas of Illinois. *Canadian Journal of Zoology* 79:581-588.
- PATTEE, O. H., P. H. BLOOM, J. M. SCOTT AND M. R. SMITH. 1990. Lead hazards within the range of the California Condor. *Condor* 92:931-937.
- PATTEE, O. H., S. N. WIEMEYER, B. M. MULHERN, L. SILEO, AND J. W. CARPENTER. 1981. Experimental lead-shot poisoning in Bald Eagles. *Journal of Wildlife Management* 45:806-810.
- WAYLAND, M. AND T. BOLLINGER. 1999. Lead exposure and poisoning in Bald eagles and Golden Eagles in the Canadian prairie provinces. *Environmental Pollution* 104:341-350.
- WIEMEYER, S. N., J. M. SCOTT, M. P. ANDERSON, P. H. BLOOM AND C. J. STAFFORD. 1988. Environmental contaminants in California Condors. *Journal of Wildlife Management* 52:238-247.