

Carpal Tunnel Release with Ultrasound Guidance

Intermediate-Term Clinical Outcomes with MRI Correlation

Grace E. Nicholas, MS², Joseph C. McGinley, MD, PhD^{1,2}, Jennifer Galloway² RN, BSN, Jennifer Hawley, RT(R) RDMS RVT²

¹University of Washington School of Medicine, Seattle, WA

²The McGinley Clinic, Casper, WY

WYOMING
W W A M I

UW SCHOOL OF MEDICINE
at University of Wyoming



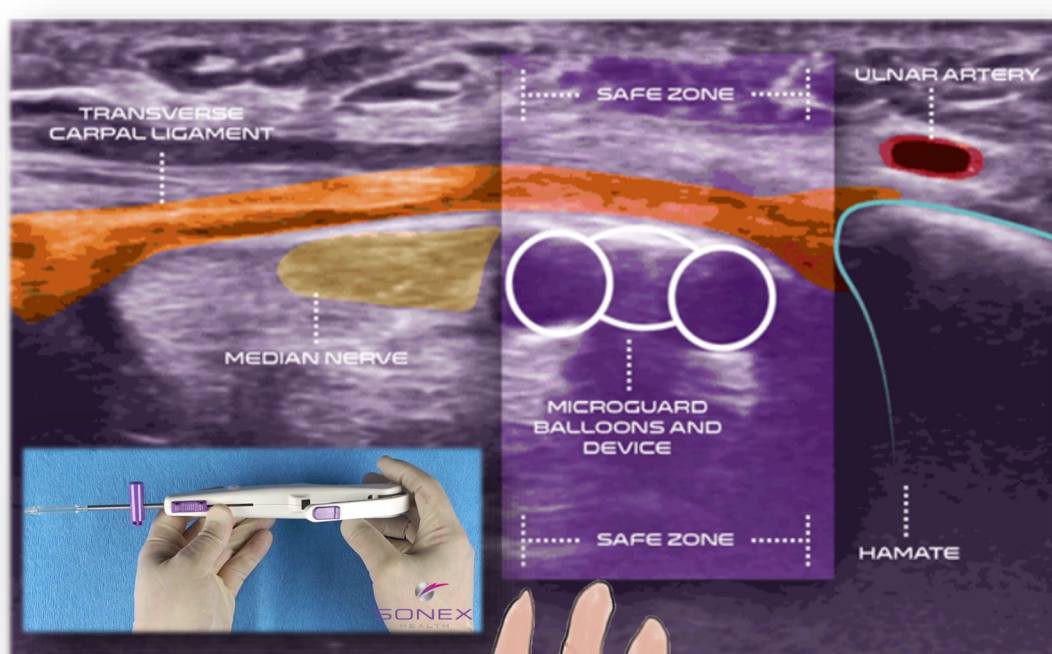
BACKGROUND

Carpal tunnel syndrome (CTS) is the most common entrapment neuropathy^{1,2} and is associated with high social and economic costs². Surgical intervention is often required to release the transverse carpal ligament, and until recently this was primarily achieved through open or endoscopic surgery.³ A less invasive technique of carpal tunnel release using ultrasound guidance (CTR-US) has provided an outpatient percutaneous procedure that has decreased the overall cost of treatment, increased safety, and allows for rapid resumption of daily activities and work.^{4,5}

The primary purpose of this study is to document short-term (2-week and 1-month) and intermediate-term (3- and 6-months) clinical results (patient reported outcomes; QDASH, BCTQ-SSS, BCTQ-FSS) of CTR-US performed by a single physician and to report morphological changes in the median nerve and carpal tunnel between pre- and post-operative Magnetic Resonance Imaging (MRI) on a subset of patients.

We hypothesize that CTR-US can be performed safely and effectively in a procedure room setting using Wide-Awake Local Anesthesia No Tourniquet (WALANT) and will allow patients to rapidly resume normal daily activities.

METHODS



At each post-operative timepoint, the statistical significance of the change in patient reported outcome scores as compared to pre-operative was assessed using a two-tailed Wilcoxon signed rank test.

The test was implemented using JMP 14.3.0. $p < 0.05$ was considered statistically significant.

MRI scans were collected pre-operatively and 3-months post-operatively. Imaging was analyzed using McKesson PACS analysis tools.



RESULTS

- A total of 61 wrists/40 patients (ages 22-87 years) met inclusion criteria, including 19 patients (47.5%) treated with simultaneous bilateral releases.
- Follow-up was available for 53 wrists at 2-weeks, 39 at 1-month, 37 at 3-months, and 20 at 6-months.
- No complications occurred.
- Work status at 2-weeks was available in 27/29 patients employed at the time of surgery. Ninety-two percent (25/27) had returned to full work duties and 2 to limited duties. One patient on limited duties reported that factors other than CTR recovery had delayed full duty return.
- Statistically significant reductions in QuickDASH and BCTQ (Boston Carpal Tunnel) scores were observed at all post-operative time-points ($p < 0.001$, Figure 1).
- Post-operative MRIs (Table 1) demonstrated TCL transection in 10/10 wrists as well as reduced median nerve (MN) flattening, increased carpal tunnel (CT) height, reduced MN edema (reduced T2 signal intensity) and a palmar shift of the MN consistent with CT decompression.

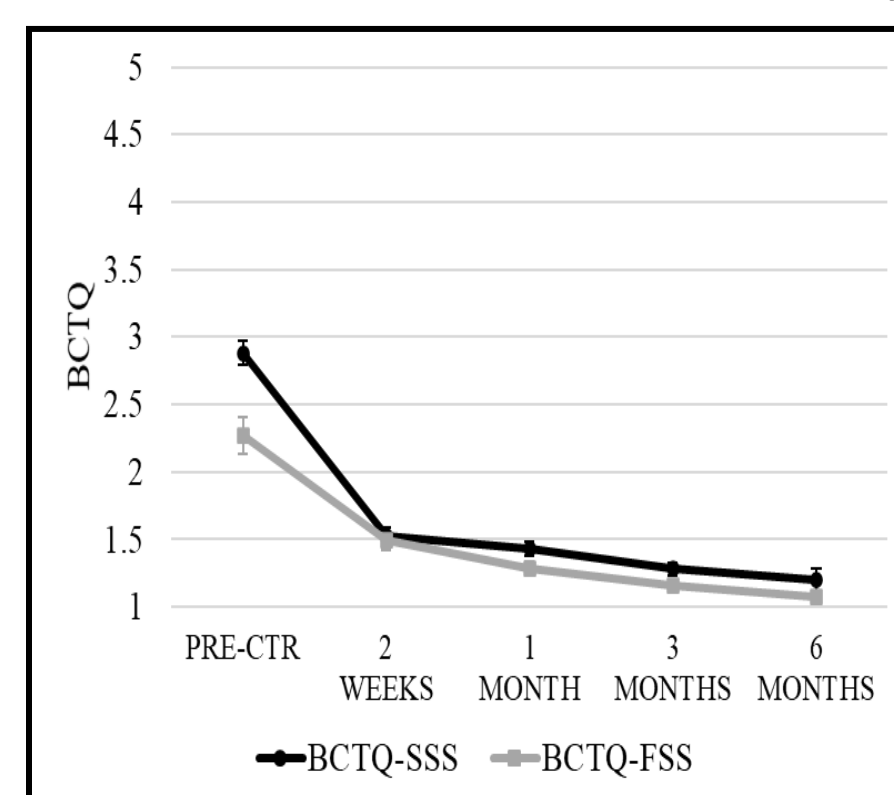


Figure 1. BCTQ-SSS and BCTQ-FSS scores (mean ± SEM) for 61 wrists in 40 patients. BCTQ-SSS = Boston Carpal Tunnel Symptom Severity Score, BCTQ-FSS = Boston Carpal Tunnel Functional Score. At all post-operative time-points, mean BCTQ-SSS and BCTQ-FSS scores were significantly reduced compared to pre-CTR ($p < 0.001$).

Table 1 Changes in MRI Parameters Following CTR-US (N=10)^a

	Hamate Level		
	Pre-Op	Post-Op	Change (%)
Palmar Shift of Median Nerve ^b	2.03 (1.42)		
Flattening Ratio of Median Nerve ^c	2.8 (0.92)	1.92 (0.47)	-31.40
Flattening Ratio of Carpal Tunnel ^c	1.95 (0.95)	1.64 (0.22)	-15.90
Maximum Height of Carpal Tunnel	11.37 (1.44)	14.2 (2.22)	24.90
Maximum Width of Carpal Tunnel	21.96 (1.68)	22.88 (2.54)	4.40
T2 Signal Intensity of the Median Nerve	963.2 (227.62)	850.3 (219.2)	-11.70

	Median Nerve Position after CTR-US ^d		
Median Nerve Position before CTR-US ^d	Nerve dorsal to line	Nerve crosses line	Nerve palmar to line
Nerve dorsal to line	0	1 (10%)	0
Nerve crosses line	0	0	9 (90%)
Nerve palmar to line	0	0	0

Data represent mean (+/- SD). All data measured in millimeters (mm).
^aMRIs performed 2-7 months following CTR-US.
^bPost-op minus pre-op distance between palmar aspect of carpal bone and center of median nerve.
^cLong cross-sectional diameter/short cross-sectional diameter. Larger flattening ratio=flatter nerve.
^dCenter of the median nerve was compared to a line drawn from the hook of hamate to the ridge of trapezium. All median nerves moved palmarly following CTR-US.

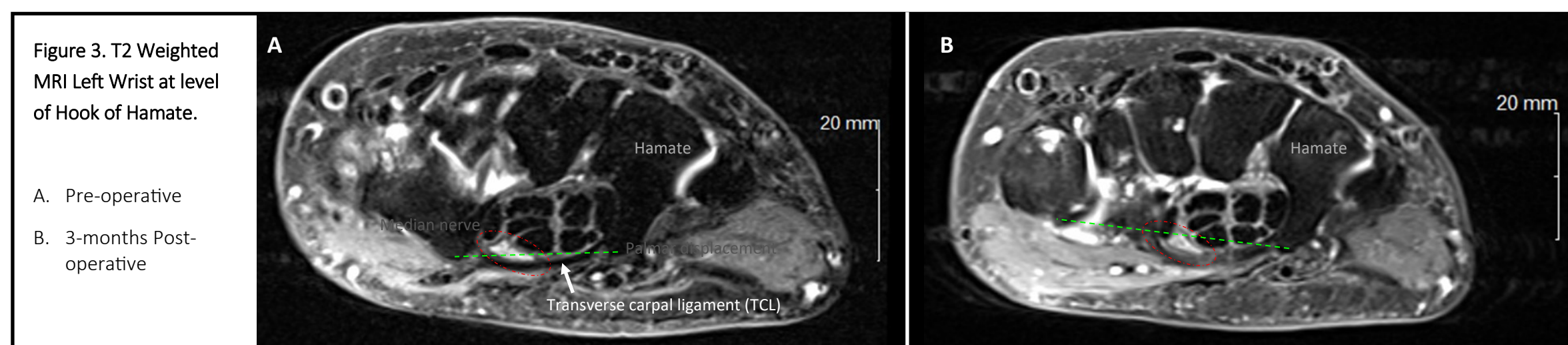


Figure 3. T2 Weighted MRI Left Wrist at level of Hook of Hamate.

DISCUSSION

All patients experienced statistically and clinically significant improvements in patient reported outcomes at 2-week post-procedure that persisted at 6-months follow-up.

MRI analysis on a subset of patients show no nerve damage-related complications at 3-months and all patients showed median nerve decompression aligning with improvement in patient reported outcomes.

A limitation to this study is the low sample size and timeframe for follow-up. Currently, data collection is continuing to include a larger subset of patients with pre- and post-operative MRI and to include long-term follow-up results (1-year).

CONCLUSION

CTR-US using WALANT in a procedure room setting is safe, effective and results in favorable morphological changes in both the median nerve and carpal tunnel as demonstrated by MRI.

ACKNOWLEDGMENTS

Jay Smith, MD and John Beckman (SONEX Health) - Statistical Analysis

REFERENCES

- ¹Atrosi I, Englund M, Turkiewicz A, Tägil M, Pettersson IF. Incidence of physician-diagnosed carpal tunnel syndrome in the general population. *Arch Intern Med.* 2011;171(10):943-944. doi:10.1001/archinternmed.2011.203
- ²Palmer DH, Hanrahan LP. Social and economic costs of carpal tunnel surgery. *Instr Course Lect.* 1995;44:167-172.
- ³Petrover D, Hakime A, Silvera J, Richette P, Nizard R. Ultrasound-Guided Surgery for Carpal Tunnel Syndrome: A New Interventional Procedure. *Semin Intervent Radiol.* 2018;35(4):248-254. doi:10.1055/s-0038-1673360
- ⁴Rojo-Manaute JM, Capa-Grasa A, Chana-Rodríguez F, et al. Ultra-Minimally Invasive Ultrasound-Guided Carpal Tunnel Release: A Randomized Clinical Trial. *J Ultrasound Med.* 2016;35(6):1149-1157. doi:10.7863/ultra.15.07001
- ⁵Petrover D, Silvera J, De Baere T, Vigan M, Hakime A. Percutaneous Ultrasound-Guided Carpal Tunnel Release: Study Upon Clinical Efficacy and Safety. *Cardiovasc Intervent Radiol.* 2017;40(4):568-575. doi:10.1007/s00270-016-1545-5. US photo www.sonexhealth.com