

Wyoming State Veterinary Laboratory Newsletter – September 2004

University of Wyoming
Department of Veterinary Sciences
1174 Snowy Range Road
Laramie
WY 82070
<http://wyovet.uwyo.edu/>

Main office/Director
Phone: 307 742 6638
800 442 8331 (Toll-free Wyoming only)
Fax: 307 721 2051

WEB case access:
<http://wsvl-web1.uwyo.edu:8083/Login.asp>

To phone laboratories directly
307 742 6681 + EXT. BELOW

Mail Room	122
Virology Lab	162
Bacteriology Lab	132
Parasitology Lab	182
Toxicology Lab	233
Clinical Path Lab	182
EM Lab	151
Regulatory Serology	142
Diagnostic Serology	163
Virologist (post vacant)	161
Dr. Merl Raisbeck	231
Dr. Ken Mills	131
Dr. Don Montgomery	204
Dr. Todd Cornish	191
Dr. Beth Williams	211
Dr. Donal O'Toole	104
Dr. Bill Jolley	181
Dr. Lee Belden	766 2134
Dr. Gerry Andrews	766 3139
Dean Frank Galey	766 4133

WNV Coordinator for WY:
Terry Creekmore: 307-742-6681, Ext. 105
(If Terry unavailable, call Dr. Todd Cornish
307-742- 6681 Ext. 191)

WSVL Advisory Board:

Dr Mike Driscoll	Mr. Ed Weppner
Dr. Jim Briddle	Mr. John Morris
Dr. J.D. Fox	Mr. Bill Lambert

[HTTP://UWADMNWEB.UWYO.EDU/VETSCI/](http://uwadmnweb.uwyo.edu/vetsci/)

MESSAGE FROM THE DIRECTOR

STUDENTS IN THE LABORATORY

I write this on the weekend of the College of Agriculture's **Brand of Excellence scholarship banquet**. This is when undergraduates and graduate students at UW are recognized financially for hard work ± fiscal need. Some 124 students in the college of agriculture received scholarships this year. Another 59 received scholarships from other pots of gold within the university, such as the Presidential and Trustees' scholarships. Of 124 college recipients, 25 (that's 1 in 5) majored in Animal and Veterinary Sciences and another 14 (1 in 10) majored in Microbiology. We expect ~5 students from these two programs to go on to veterinary college this year.

The laboratory uses student workers to help operate its various units. Frankly, without reliable undergraduates we could not run the laboratory. For our part, we use this time to identify and recognize students who are academically gifted and have a strong work ethic. This ensures that faculty members can write solid letters of recommendation for students to go with their veterinary school applications. Most students heading to veterinary school from Wyoming have worked at the WSVL. Benefits flow in both directions. The students we hire are the ones we think will learn most from the experience.

There are two scholarships in the college that are specifically targeted at undergraduates going on to a professional veterinary program. The **Rue Jensen Veterinary Scholarship** was established in memory of Dr. Jensen, a former dean at CSU and for some years a diagnostician at the WSVL. The **Joe S. Gloyd scholarship** was established in 2004 by Dr. Joe Gloyd and his wife Kathy. Old hands may remember Joe from his time in the state, when he served 10 years on the Wyoming Board of Veterinary Medicine. He currently runs a veterinary consulting company out of Delaware. A third scholarship, the **Noreen Ring veterinary scholarship**, will be endowed later this year to commemorate the mother of a faculty member in Veterinary Sciences. It is targeted exclusively at pre-veterinary students.

If you or your family is interested in supporting pre-veterinary scholarships, please contact me or Anne Leonard in the development office at the College of Agriculture (307 766 3372; ALEONARD@UWYO.EDU). Financial need is a major constraint on students hoping to enter the profession. You can help offset these costs, and ensure that young people with the right stuff will enter the profession.

The department recently received an endowment for another program: the **Wildlife Disease Veterinary Internship** which Dr. Williams established in 1983. It is currently run by her and Dr. Cornish. This is designed to

attract junior and senior students from veterinary colleges across North America to the Wyoming State Veterinary Laboratory for 3 – 9 weeks. During this time they conduct disease investigation under faculty supervision, and participate in necropsies and field visits with WSVL faculty members and Wyoming Game and Fish Department biologists. The endowment will allow us, for the first time, to offset the costs students have in coming and staying here. It will also defray their expenses when they take the internship for academic credit at UW. Until this is put in place, they come and are taught as “invisible beans.” They were not a recognized part of the department’s teaching mission, in spite of faculty time devoted to them.

Training the next generation of veterinarians, microbiologists and diagnosticians is a critical but unseen component of what goes on in your state veterinary laboratory. If you are interested in financially supporting this aspect of our mission, please contact me or Anne Leonard at the College’s development office.

Donal O’Toole

DIAGNOSTIC CASES OF INTEREST

Seminoma in a stallion

A stallion was examined for a rapidly enlarging mass in the right testicle. Ultrasound suggested neoplasia. Histological examination revealed a neoplastic mass composed of pleomorphic germinal cells consistent with seminoma. The mass had a predominantly extratubular pattern of growth, replacing and distorting testicular parenchyma. Neoplastic cells were present in lymphatics.

Seminomas should be regarded as at least potentially malignant neoplasms in all domestic species. This is especially true of those with an extratubular growth pattern. The incidence of confirmed metastatic disease is low, however. Seminomas in horses are uncommon compared with dogs. According to one text, metastatic disease is more likely in stallions than dogs.

Dr. Don Montgomery

Post-vaccination endotoxemia in cattle

A calf died approximately one hour after receiving two respiratory vaccines. Microscopic lesions in the lung consisted of congestion, mild alveolar hemorrhage, and alveolar accumulation of proteinaceous fluid mixed with fibrin and few leukocytes. Alveolar capillaries contained fibrin deposits (thrombi). Considerations for acute death following vaccination include acute allergic reactions or anaphylaxis, and endotoxemia.

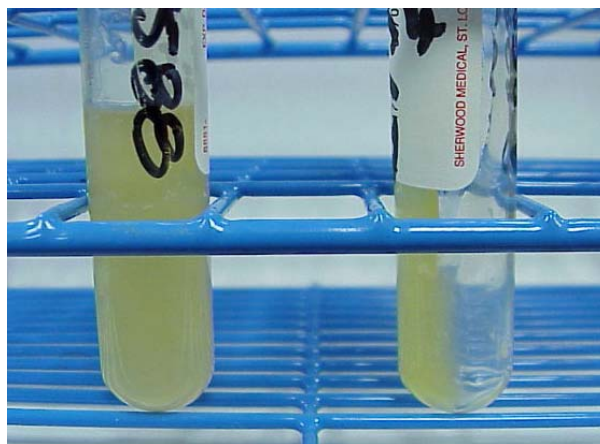
Endotoxemia was the primary consideration in this case based on the presence of fibrin thrombi in alveolar capillaries. Some individuals seem highly susceptible to endotoxemia but, depending on the concentration of endotoxin in parenteral solutions, multiple death losses can also occur. Such cases should be reported to the Center for Veterinary Biologics, since the problem may portend a bad lot of vaccines.

Dr. Don Montgomery

Antibiotic-response “summer arthritis” in lambs at high altitude – presumed *Chlamydia* arthritis

We need your help on this.

A syndrome of lameness associated with synovitis and tenosynovitis has been recognized in south central and southwestern Wyoming as well as contiguous states in recent years. It occurs through summer months into early fall. According to one producer, cool fall weather and grazing at high altitude seem to be associated with worsening of the condition. Morbidity is high but mortality associated with the syndrome is low. Lambs commonly respond to antibiotics. It is a big problem in flocks where the producer is committed to producing antibiotic-free, organic lambs.

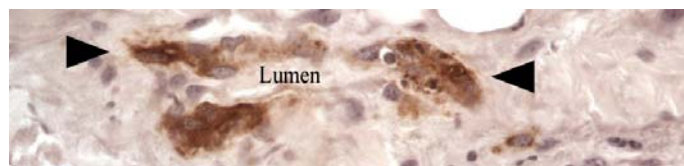


Arthritis in lambs: fluid collected from swollen joints is thick, viscid and clots readily. To date no viral, mycoplasmal or chlamydial agents have been isolated from such samples. We’d appreciate hearing from anyone who recognizes a similar syndrome in lambs grazed at high altitude during summer and fall months.

Recently, three lambs were examined at WSVL with lesions suggestive of a septic process. Testing is still in progress. To date, routine bacterial culture and mycoplasma testing have been negative. Despite advances in testing for infectious or septic joint disease including PCR, confirmation of a specific cause is often difficult. One reason for this difficulty is duration of infection. By the time lambs become obviously clinically lame, the disease may be at least several days duration, limiting the ability of labs to confirm a primary cause. Lambs were submitted to CSU in a past year but a specific etiology was not established. Dr. Montgomery went out to one flock to get additional samples for culture from live, lame lambs.

One lamb examined by Dr. Montgomery had a joint in which there was distinct vaculitis in connective tissue of the joint. Even though tissues from the lamb was culture- and PCR-negative for *Chlamydophila abortus* (the helpfully confusing new name for *Chlamydia psittaci* – bacteriologists only do this to confuse the heck out of pathologists), when sections of multiple joints were stained for chlamydial antigens, one came up positive. It was the one that had the vasculitis, and the only place where antigen was present was in endothelial cells, and around vessels. We don’t like to call

things based in immunohistochemistry alone, but we strongly suspect that the causative agent is our friend, *C. psittaci* (*Chlamydophila abortus*). The producer will be encouraged to vaccinate for this. We would still like to get a laboratory isolate, possibly for an autogenous vaccine.



Arthritis in lambs: IHC preparation of a small blood vessel of a lamb with typical signs. There is intense brown staining (arrowheads) in some cells in the wall of the blood vessel. The antibody detects antigens of Chlamydia. Lumen: lumen of blood vessel. Photo: Dr. DM

If you recognize this syndrome in sheep at high altitudes and have a producer who would give us access to acutely affected sheep, please contact Dr. Montgomery. Most information we have is coming from producers. We would like to get a veterinary perspective on risk factors and response to treatment, and access to acutely affected lambs.

Hepatic encephalopathy in a horse fed fireweed (*Kochia* sp.)

Kochia is a common plant in Wyoming, typically seen along the edges of fields, recently disturbed soils, waste ground and, most abundantly, in the front gardens of some veterinary pathologists. It is associated with two disease syndromes: polioencephalomalacia, probably due to its ability to accumulate sulfate, and hepatic disease with photosensitization.

A thin 12 year old mare in the Cody area showed signs of colic and became depressed. Clinical chemistry demonstrated elevated serum enzyme activities suggestive of hepatic disease. Overt neurological signs developed: ataxia, difficulty swallowing, pacing. She tested negative for WNV IgM antibodies. Her condition deteriorated; she became aggressive and began to bite at handlers and was sent to God. At necropsy the veterinarian noted jaundice and a firm, yellow liver with gallstones in the bile duct. Histology confirmed the clinical diagnosis of hepatic encephalopathy. She tested negative for the other differentials: rabies, WNV encephalitis, and evil spirits. There was moderate diffuse portal fibrosis with bridging, bile duct hyperplasia and perivenular fibrosis. Glial changes in gray matter of the brain were indicative of hepatic encephalopathy.

The veterinarian examined the pasture where the mare and her companion were kept. The pasture was grubbed down to dirt and rocks. Hepatic serum enzyme activities in the companion horse were elevated. The hay being fed was certified weed-free, but some bales consisted almost exclusively of *Kochia*. The companion was taken off the hay, which was bought from a property north of Cody. Subsequently the veterinarian examined a group of horses that were fed hay from the same source. He bled 9 of the 50 horses; 4 had elevated serum enzyme activities. The horses

were taken off the hay. One horse was subsequently bled and at that time serum enzyme activities returned to normal.

The presumed cause of primary hepatic disease in the horse, and possibly the companion horse and a second group of animals fed hay from the same source, was *Kochia*. The hepatotoxic principal in *Kochia* is undefined. Typical lesions consist of hepatocellular swelling, degeneration and death, with fibrosis. Some animals have a distinctive brown birefringent pigment in bile ducts, but that was not present in this case. *Kochia* becomes a problem when it is a major part of the diet (at least 50%).

Some lesions: not all horses that are sick in the head have WNV; if you see a horse with advanced CNS signs, please submit the brain AND other tissues. The finding of one sick horse, and evidence that the disease is feed-associated, should trigger transsynaptic firing inside your head when you encounter other animals on the same diet.

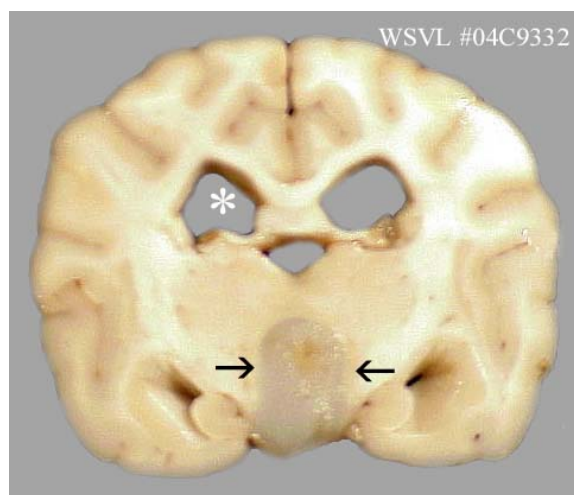
This was a good diagnostic call by the veterinarian.

Drs. Don Montgomery, Merl Raisbeck and Mel Fillerup

Brain tumor in a young beagle

A five-year-old Beagle was presented to a clinic in Sheridan WY with neck pain at C₂-C₃. It had previously been treated at other clinic with nonsteroidal anti-inflammatory drugs. The Sheridan clinic treated it with acupuncture, hot packs and massage and the dog appeared to respond. Therapy was repeated the following morning, but that afternoon the dog was found dead in its cage. The dog's carcass was submitted to determine the cause of clinical signs and the cause sudden death.

When Dr. Montgomery examined the brain, there was diffuse brain swelling with acute caudal displacement of the terminal brainstem and cerebellum. A translucent gray mass was in the ventral portion of the brain at the level of the infundibulum. The mass extended into and obliterated portions of the third ventricle with peripheral displacement of brain tissue. There was slight dilation of lateral ventricles. No gross or microscopic lesions were found in the cervical vertebral column or spinal cord.



WSVL#04C9332. Brain slice from a beagle with neck pain. Note area of discoloration in ventral

midline thalamus (between arrows) with mild hydrocephalus (asterisk). Histologically the mass was an oligodendoglioma.

The mass was typical of a primary brain tumor of glial origin, an oligodendroglioma. Oligodendrogliomas are typically found in dogs 5 years of age and older. Boxers, Boston terriers, and bulldogs seem predisposed. Clinical signs depend on the area of the brain affected. Acute death in this dog was attributed to acute brain swelling and displacement. Although rare, brain tumors occur in dogs and should be kept on the differential list when dogs present with progressive CNS signs. Interestingly, the owners had another dog that developed a brain tumor which responded to successful surgery

Dr. Don Montgomery
October 4, 2004

***Brucella ovis* ELISA**

Recently we began to have a series of “positive” or “suspect” *B. ovis* results that did not square with what the owners thought was the health status of their flocks. This caused us to check with other laboratories to see if they were having the same experience. The short answer is YES. Additional testing, and a lot of work by Becky Wills in the regulatory serology section, confirmed that we received a dud batch of antigen from the USDA National Veterinary Services Laboratory. It was giving us false suspect and positive reactions. The test standards (known positive and negative serum provided by NVSL) were also unsatisfactory.

Back when we first offered this service, we said the assay was not great but that we would make sure it matched up with testing by other laboratories in the area. It seems that we are still matching but we are unhappy with the assay. There is an intermittent problem with the antigen supplied by USDA in that laboratories get consistent results with some lots of antigen, and unable to get decent results with others.

The director of the USDA’s National Veterinary Services Laboratory was contacted about the problem. When he visited the WSVL in October the problem was discussed with him at length. He promised to get it sorted out. NVSL recognizes that one batch of antigen was bad.

Dr. Gerry Andrews in this department is going to have a run at getting a grant from the USDA to develop a better test using cleaner antigen.

If you have clients who have received results that just don’t make sense, please let them know that the problem is not at our end – we stopped using the bad antigen as soon as we recognized the problem.

Dr. Ken Mills
September 2004

Acute Lupine Poisoning in Lambs

In August of this year, we received tissues samples from two lambs which were part of a flock of approximately 1000 animals grazing on a Forest Service pasture at 8000'. Shortly after being moved to the pasture, the herder started to find dead lambs. Lambs were clinically normal in the morning and dead in the evening. The few which lived long

enough to be examined exhibited head tilt, circling, stumbling and prostration prior to death.

Histological lesions were typical of agonal struggling, but provided no clues to explain the clinical signs reported. In particular there was no polioencephalomalacia. Clinical pathology included elevated serum sodium, CK, and glucose. Brain sodium was normal in one lamb and slightly elevated in the other. A toxic element screen revealed slightly elevated lead (2.5 ppm) in one lamb, but nothing in the second. An alkaloid screen of urine produced two unidentified spots on thin layer chromatography, one of which matched lupanine when compared to the NIST MS library. A sample of rumen from the lambs was sent to Dr. John Reagor of TVMDL. Dr. Reagor indicated that the sample was loaded with *Lupinus sp.*

A discussion with the owner indicated that the flock was grazing on heavy stands of lupine, but he didn’t attribute significance to the observation because a second pasture a few miles away also contained lupine and sheep there were unaffected. He felt that the salt was somehow involved because the mortality in the problem pasture seemed to occur within the first 3 days after placing (weekly) a new batch of salt. We checked a sample of salt for pesticides with (negative results and identified the weeds growing around the salt licks as Syrian Mustard.

To the best of my knowledge, this is the first episode of acute (neurological) lupine poisoning that the WSVL has investigated. The plant is more commonly associated with the teratogenic condition known as “crooked calf disease”. Acute intoxication is believed to result primarily from lupanine. Signs usually occur within a few hours of ingestion of a toxic dose and consist of twitching, nervousness, ataxia, dyspnea and prostration. Death results from respiratory paralysis.

Not all lupines are toxic. There can be significant variation in the toxicity of the same species from location to location and year to year. The dose response curve for lupine alkaloids is steep, which means the difference in dose between no toxic effect and lethality may be small. In this case, we hypothesize that lambs in the upper pasture which were receiving salt only intermittently, were more inclined to eat the bitter lupine and thus received a slightly larger dose.

Dr. Merl Raisbeck,
Marce Vasquez
Dr. Don Montgomery
September 20, 2004

Heartworm refresher ‘04

Wyoming continues to remain relatively free of endemic canine heartworm infections, compared with states on our borders. Within the last 15 years, only 4 “native” dogs tested positive for *Dirofilaria immitis* at the WSVL. The travel history for those animals is unknown, although 2 were reportedly not taken out of Wyoming from birth until they were found infected. Many more canines from

heartworm-endemic states were brought into Wyoming and found infected after arrival; a few of those born in Wyoming acquired heartworm after spending time in an endemic state during the season of vector activity.

This article is intended to refresh awareness of factors relative to detection of newly infected hosts. Whereas infected animals are most likely to come from endemic areas outside of Wyoming, new infections may originate within our borders. Several species of *Aedes* and *Culex* mosquitoes, important vectors of *D. immitis*, thrive in various areas of our state. If a dog with a patent heartworm infection (microfilariae in the blood) is imported to an in-state area where the good vectors thrive, an evening blood meal on the reservoir canine will initiate the process in the vector that leads to transmission to local dogs. In addition to the potential for transmission to dogs in interior areas of Wyoming through imported canine reservoirs, there is a higher likelihood of the worm infesting animals in areas near our borders, where major rivers and streams flow into the states around us, all of which harbor endemic dirofilariasis. These include the Big Hole, Belle Fourche, North Platte, Green and Snake rivers in northern, northeastern, southeastern, southwestern and west central areas of Wyoming, respectively.

Heartworm prevalence in our state is probably higher than we realize, because our limited dataset is based on diagnostic results from blood samples tested at WSVL. An unknown number of veterinary clinics perform the ELISA and/or Knott's test on samples from clients' animals.

Some important factors related to effective testing should be considered:

- Newly infected dogs will normally not test positive by ELISA until 5-6 months after acquiring the new infection, therefore, a dog infected during the mosquito season (June-September in most of Wyoming) will not produce an accurate diagnostic result by ELISA until November (earliest) to February/March.
- Newly infected dogs will not exhibit patency (microfilaria in the blood) for 7.5 to 8 months after infection. If examined for microfilaria, a blood specimen should be collected between about 6 and 8 PM, during which time the embryos are known to be at highest concentration in peripheral blood.
- Dogs may be infected with adult worms, but harbor no microfilariae. If only male OR female worms are present, microfilariae will not be produced. This situation necessitates an ELISA for detection of the infection.
- Dogs may harbor microfilariae, but test negative with the ELISA. Filarid worms, other than *D. immitis*, especially *Dipetalonema reconditum* are often nonpathogenic and may be present in the absence of *D. immitis* and will not test positive with the *D. immitis*-specific ELISA. Also, microfilariae have been known to enter puppies *in utero*, and remain in the circulation after birth for 2 to 8 years.
- Many infected dogs, especially those with less than 25 adult worms, will not exhibit clinical signs of infection. Those with 45-50 adult worms will

usually show moderate clinical signs and those with 60-100 worms exhibit serious, often lethal respiratory/cardiovascular effects. Most newly infected animals will exhibit no clinical signs from day 1 until about 8-9 months after infection.

- Many owners of heartworm-infected dogs refuse to submit their animals for treatment, thereby maintaining a reservoir of infection in their community.

A survey is currently being planned to collect mosquitoes in specific areas previously mentioned and to test them for *D. immitis* larvae. The polymerase chain reaction test will be used to identify any filarid larvae found in the vectors' salivary glands. The survey results are expected to reveal more accurate distribution and prevalence data for the heartworm in Wyoming, than has been generated by testing the intermediate host canine population. For more information, please contact Bill Jolley at WSVL.

Dr. Bill Jolley
15 September 2004

NEW TESTS

Nested PCR for canine distemper

Canine distemper is fairly easy to diagnose in dead dogs, since lesions are characteristic. We have a good cheap fluorescent and immunohistochemical tests. Nice inclusion bodies occur in multiple tissues (stomach; lung; bladder; renal pelvis; brain) to delight the pathologist.

The real challenge is confirming a diagnosis of CDV in a live dog. As some of you know, we had a rash of cases in Riverton and Lander earlier this year, and we're still seeing cases from Riverton in September. The virus is hard to grow, and in live dogs there is limited access to tissues where the virus replicates. We use conjunctival smears from suspects, but generally there are so few cells present in such preparations that making the call on a fluorescent antibody test is dodgy – there are lots of false negatives. An alternative is looking for viral nucleocapsids by electron microscopy, but this is a tedious way to make a diagnosis. The success rate is low unless many nucleocapsids are present.

Jackie Cavander and Dr. Cornish in Virology Section are working on a nested reverse transcription PCR reaction (nRT-PCR) that shows promise as a test to use in live dogs. If you have a live dog on which you need to rule out CDV, please consider submitting conjunctival material on a swab AND whole blood for a CDV N-PCR test. The test successfully detected CDV in every tissue we've run (8 cases so far) that stained positively by FA (regardless of the amount of staining) and on 1 of 2 sets of swabs we received from live animals with appropriate clinical signs for CDV. The swab in which it did not work was an unsatisfactory sample, since it had already been processed for VI so that most material was already removed from swab, and it then spent several days in the garbage. The increase in speed over virus isolation on samples from live animals combined with the conjunctival slide FA problem makes it a promising test for live animals.

Dead animals are another story. The FA on frozen tissues is sensitive and specific and corresponds well with isolations on the same tissues. PCR is therefore less likely to be cost effective on dead animals, although of course it can still be run.

Fever (biphasic), anorexia, depression, leukopenia (especially lymphopenia), followed by oculonasal discharges, respiratory signs (cough, harsh lung sounds, exercise intolerance, radiographic evidence of bronchointerstitial pneumonia), GI signs (vomiting, diarrhea, etc.), evidence of secondary bacterial or parasitic infections (pneumonia especially, GI possible), with or without classic "hardpad" lesions - hyperkeratosis of footpads and nasal planum - with or without neurological disease. Neurological disease can follow the above classical signs or occur in absence of above signs. Common neurological signs include: localized involuntary muscle fasciculation, spasms, myoclonus; paresis or paralysis, usually ascending; convulsions/seizures, starting out with salivation and rapid chewing movements, and sometimes progressing to grand mal seizures, coma and death. Neurological signs may lag behind systemic signs or infection by weeks or even months. Differential diagnoses are legion (dependent upon clinical manifestation in individual dog). They include other viral infections (including rabies, WNV, parvovirus, adenovirus, coronavirus, etc.), bacterial infections, parasitic/protozoal infections, toxicoses, and immune-mediated diseases.

The test:
CDV nRT-PCR
Submit:
Green-top blood (heparin) and conjunctival swab
Cost:
\$35

Four cases of delusional parasitosis in Wyoming citizens

Officially known as **delusional parasitosis**, this condition has involved (non-clinically) several veterinary practitioners in Wyoming and diagnostic personnel in the parasitology section of the WSVL at least 4 times in the past 29 years (as recorded in the fading memory of Bill Jolley). The veterinarians in each of the 4 cases knew individuals involved with the bizarre condition, and channeled them to us at the laboratory. Medical practitioners, with whom we have limited contact, are probably more often exposed to the condition than are veterinarians and those of us at laboratory. But the fascinating individual aspects of each case is worthy of our awareness of the condition in general.

Recognition of potential delusional cases by veterinarians should be facilitated by the knowledge that humans harbor parasitic ecto- and endoparasites similar to those commonly found on and in production and companion animals. It is likely that as a veterinarian explains details of an infection of giardiasis, for example, to a client with an infected animal, those clients with potentially delusional thought processes will obsess about the possibility that they and/or other household members are infected. Information about zoonotic agents, accessible on the web, in health

magazines and other articles, is often written for shock value. It serves to promote the fear factor in certain individuals.

Case 1: A woman in north central Wyoming, while picking up her dog after a routine procedure, described to her local veterinarian a condition she was convinced was a skin invasion by insects from berry bushes in her yard. The veterinarian was a patient, personable individual, who accommodated the client's request to "have a look at the holes in the skin on her arms". He agreed that the bumps and excretions appeared unusual, and advised her to contact the local extension agent, who in turn, called an extension entomologist at UW. The extension entomologist communicated with the woman, and asked her to have a staff at a local medical facility collect samples of the lesions on her arm, and to forward them to UW for analysis. The samples were submitted, the entomologist examined them and found no evidence of arthropods, and forwarded the sample to the WSVL. Microscopic examination (60x – 1000x) of the samples revealed only thick, pulpy deposits of sebaceous secretions. The final outcome of diagnosis in this person – i.e., what caused the bumps – is unknown.

Case 2: A young mother in western Wyoming noticed "worms" in her 5-year-old son's stool. She was sure that some were crawling and/or swimming in the water. The boy was taken to a non-traditional health facility in Salt Lake City, where a fresh stool was induced from the boy and examined. The resulting diagnosis was roundworms and "E. coli" (presumably *Entamoeba coli*, a non-pathogen). Herbal remedies were prescribed and the family sent home with instructions to return for follow-up examination after 30 days. After returning home, the nervous mother continued to see "worms" in her son's stool for the next 4 weeks. Concerned that the medications were ineffective, she called a local veterinarian, who was a family friend. The veterinarian referred her to us at the WSVL, which quickly resulted in submission of a visibly "worm-positive" stool to the parasitology unit. The "worms" in the sample were the somewhat droplet-shaped cells from a citrus-type fruit, which in this case was grapefruit. Careful further examination did not reveal protozoan or helminth agents.

Case 3: A young man participated in a sheep roundup in south-central Wyoming, where animals were processed for deworming and various other procedures prior to being loaded onto trucks for transport. During the handling process he saw and inadvertently touched numerous keds (*Melophagus ovinus*) and/or ticks, concentrated in the usual sites on the animals. Within a week the young man had scratched his neck, chest and back of his head to the degree of significant bleeding. His family physician reassured him that he was not infested and prescribed sedatives to enhance his sleep quality and medications to prevent secondary skin infections and relieve irritation. Several weeks after some relief, he described his experience to the veterinarian who was a personal friend, and who also participated in processing the sheep. The veterinarian relayed the story to us at the WSVL.

Case 4: Recently, a man in northwestern Wyoming was thought to be infected with a worm, possibly a tapeworm, based on the size and shape of "structures" visible in his feces and frequently passed in nasal/oral discharges. Initial attempts to identify the "worm" for possible treatment

were unsuccessful. A local veterinarian was consulted (details unknown), and obtained and shipped some specimens to the WSVL. Microscopic examination of the specimens revealed mucoid “scabs”, or “scales” from the nasal passages, most of which had a few pine, grass and/or shrub pollen, clumps of and individual epithelial cells, and hairs/hair fragments “glued” to the proglottid-like particles. No evidence of parasitic agents was found. Cytological examination revealed inflammatory exudates only.

We can only imagine the number of cases of this kind that medical practitioners encounter during a “normal” year of service. Be aware. Please consider sharing any personal experiences of the type described here. Cases like these are valuable teaching tools in the Medical Parasitology courses taught for undergraduates and the first-year medical education (WWAMI) students.

Dr. Bill Jolley
Parasitology
September 20, 2004

Note: The veterinary laboratory examines unusual accessions such as these for zoonotic agents only. We do not attempt to make diagnoses of human diseases. *DO'T*

Does *Tritrichomonas foetus* cause chronic diarrhea in cats?

Over the past several years a series of reports have associated *T. foetus* with diarrhea in cats. Most – essentially all - of this work came out of one research laboratory in North Carolina State University. The relationship between *T. foetus* in cats and the same agent in cattle – particularly whether they are the same strain or are species-specific – is unresolved. Several laboratories offer a PCR to detect *T. foetus* in cat poop.

The story of an association between diarrhea in cats and *T. foetus* goes something as follows. In 2001 an article was published in the American Journal of Veterinary Research describing the effects of exposing cats via the orogastric route to *T. foetus* from a kitten with diarrhea. Experimentally-exposed cats developed diarrhea, with the worst signs in cats concurrently infected with cryptosporidia. The trichomonads were seen on feline mucosal surfaces of ileum, cecum and colon examined by biopsy and at post-mortem. Subsequently there was an interesting disagreement about whether the organism involved might be *Pentatrichomonas hominis* (a five flagellated human trichomonad). A study appeared to show that *T. foetus*, not *P. hominus*, was most consistently associated with chronic diarrhea in cats. Subsequently the NC group demonstrated that the *In Pouch* system used for trich in cattle also works for cats with enteric trichomoniasis – fecal samples the size of a grain of rice are placed in the pouch and shipped to the laboratory for examination. A study of cats, presumably healthy, at a cat show by the same group in 2004 reported a high prevalence of infection (31%; 36/117 animals). On the basis of a survey of owners, the researchers concluded there was a strong association between *T. foetus* and diarrhea in the home catteries; 70% of all owners surveyed reported diarrhea in their cattery in the previous 6 months.

Features of *T. foetus*-associated diarrhea, as reported by the NC group, are:

- Chronic infection over extended periods (up to 2 years)
- Waxing-waning large bowel diarrhea with occasional fresh blood and/or mucus
- Feces vary from semi-formed to soft/unformed.
- No systemic illness
- Improved fecal consistency and disappearance of trichomonads during administration of antimicrobial drugs, with return of diarrhea and trichomonads shortly after drugs are discontinued.
- Eventual resolution of clinical signs in most cats by a median time of 9-months after clinical onset
- Lesions of mild to “severe” lymphocytic-plasmacytic colitis
- Trichomonads can only be reliably detected in biopsies by immunohistochemistry. Otherwise, lesions are non-specific and are without detectable organisms.
- There is no statistical association with proximity to cattle or swine agricultural operations, drinking from the toilet, or eating table scraps, or other disgusting habits to which cats are prey.
- Dietary changes using prescription diets and other means may help resolve the diarrhea, but can also prolong the duration of infection.

Idiopathic diarrhea is common in cats. At the WSVL we have never made an association of *T. foetus* with chronic diarrhea. We think it unlikely we missed it on direct fecal examination but – anything is possible. The NC group reports that culture in modified Diamond’s medium and, better still, a single-tube nest PCR method is the technique of choice. The PCR amplifies a conserved portion of the *T. foetus* internal transcribed spacer region (ITS1 and ITS2).

Bottom line, we’ve never seen it, and literature making this association with diarrhea would be more convincing if other laboratories reported the same association (the ability to replicate observations made by other scientists is known technically as “science”). But prove us wrong. If you have a cat with chronic idiopathic diarrhea and want us to check for *T. foetus*, please contact the parasitology laboratory.

1. Gookin JL, Levy MG, Law JM et al: 2001, Experimental infection of cats with *Tritrichomonas foetus*. *Am J Vet Res.* 2001 Nov;62(11):1690-7
2. Levy MG, Gookin JL, Poore M et al: 2003, *Tritrichomonas foetus* and not *Pentatrichomonas hominis* is the etiologic agent of feline trichomonal diarrhea. *J Parasitol.* 2003 Feb;89(1):99-104.
3. Gookin JL, Foster DM, Poore MF et al: 2003, Use of a commercially available culture system for diagnosis of *Tritrichomonas foetus* infection in cats. *J Am Vet Med Assoc.* 2003 May 15;222(10):1376-9.
4. Romatowski, J. 1996. An uncommon protozoan parasite (*Pentatrichomonas hominis*) associated with colitis in three cats. *Feline Pract.* 24:10-14.
5. Romatowski, J. 2000. *Pentatrichomonas hominis* infection in four kittens. *J. Am. Vet. Med. Assoc.* 216:1270-1272.
6. Gookin JL, Stebbins ME, Hunt E et al: 2004, Prevalence of and risk factors for feline *Tritrichomonas foetus* and giardia infection. *J Clin Microbiol.* 2004 Jun;42(6):2707-10.

7. Moster DM, Gookin JL, Poore MF et al: 2004, Outcome of cats with diarrhea and *Tritrichomonas foetus* infection. J Am Vet Med Assoc 225: 888-892.

From: The Wyoming State Veterinary Laboratory
Department of Veterinary Sciences
University of Wyoming
1174 Snowy Range Road
Laramie, WY 82070
<http://wyovet.uwyo.edu/>

To: