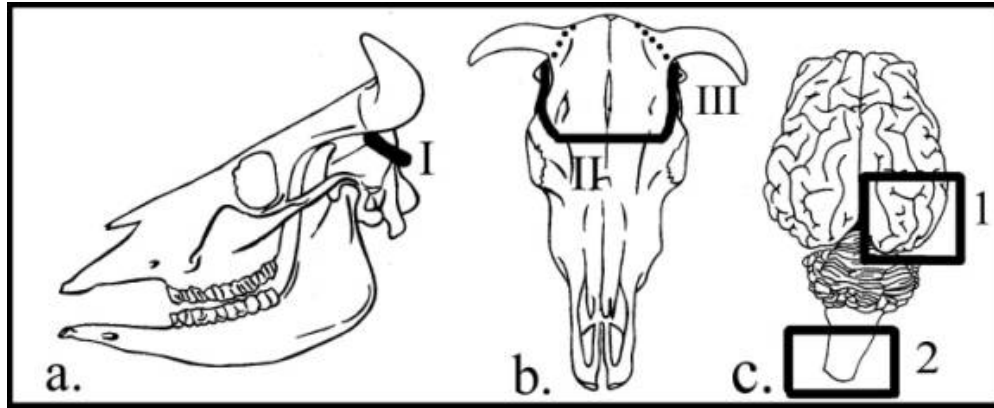


SAMPLING BRAINS POST-MORTEM

Brains are fragile organs and should be treated as such. From time to time our laboratory receives brains for evaluation that are macerated, crushed, badly fixed, or improperly sampled. Described below are instructions for when and how to take out a brain, and how to sample it for microbiology and pathology. An important point to remember is that brains, unlike many organs, cannot be randomly sampled. Many diseases of the brain affect specific areas. The best sample to send us is an intact brain so that it can be properly and comprehensively sampled.



Legend

The ABC of brain removal

1. Make two cleaver cuts (I) at the BACK of the skull above each occipital condyle.
2. Make a third cut (II) at the FRONT of the cranial vault along a line connecting the lateral (temporal) part of the eye sockets or lateral canthus of each eye. Two layers of bone here form the roof and floor of the frontal sinus, and you have some margin for error with the top layer. The two final cuts (III) are made at the LATERAL sides of the skullcap, through the frontal and parietal bones, ventral to the horns (in cattle). If the horns are big and in the way, saw them off first.
3. In most instances, samples for microbiology require a swab of meninges between cerebellum and occipital poles (arrowhead), and a wedge of tissue from one cerebral pole (1). If you suspect rabies, listeriosis, or other diseases localized to brainstem, sample the most posterior part of medulla oblongata (caudal to fourth ventricle) for microbiology (2). The rest of the brain should be submitted intact for histopathology.

When to take the brain at necropsy:

1. When an animal exhibits neurological signs.
2. When an animal dies suddenly or unobserved.
3. When you find no gross changes in other organ systems.
4. When a "complete" necropsy is required.

How to take the brain:

Removing brains from companion animals is straightforward. If you want to be sure the brain of a cat or dog will be intact and you don't have the time or inclination to remove it, send us the intact head on ice packs. Brains undergo autolysis slowly, provided they are collected from recently dead animals and kept cool. Receiving a whole head with a mildly autolytic brain is preferable to a freshly fixed but otherwise ruined specimen. If an animal was shot in the head and you suspect neurological disease, we may be able to interpret changes, since the volume of brain tissue ruined by low-caliber bullets can be

surprisingly small. But as a general rule, never shoot animals in the skull if you would like confirmation of a diagnosis of suspected CNS disease.

The brains of adult cattle, sheep and horses are best removed with a heavy butcher's cleaver or an ax. A rat-toothed forceps, a scissors, and a fresh scalpel blade and handle are also required. It is helpful to have a bone cutting forceps and a T-wedge to lever off the skullcap, but these are not essential. A saw works well in experienced hands, but you need someone to hold the skull and it is easy to saw into the brain, thereby contaminating it.

Separate the head from the neck at the atlanto-occipital junction using a ventral approach while the head is extended. If you have time, collect CSF once intact dura mater is exposed. Use a 20-gauge needle and a 5 or 10 ml syringe - a distinct "pop" is palpable when the meninges are pierced. A cytology preparation made from CSF may give you a quick diagnosis. Sever the spinal cord at C1 as far caudally as possible. This ensures a segment of attached cord will be removed with the brain.

Put the head on a hard surface, reflect skin from the calvarium, and trim muscle and fascial tissue along the line of incision (see drawing). It particularly helps to remove the soft tissue above the occipital condyles, otherwise it hard to see what you are doing and deliver accurate blows with the cleaver. Make the first and hardest blows above and to each side of the foramen magnum. This is the thickest part of the skull. It is best to make your first cut here while the rest of the braincase is stable. Once the two occipital cuts are made, make the anterior and lateral cuts. You can be quite vigorous with the anterior cut, since two layers of bone form the floor and roof of the frontal sinus. The lateral cuts need to be made more carefully, using restrained, bouncing blows of the cleaver. The corner of the cleaver can be used to cut through remaining bridges of bone. To make sure it is free, tap exposed bone of the frontal sinus and check the skullcap is loose. Reflect the skullcap caudally, exposing brain with overlying meninges.

If you suspect an infectious process, nick the meninges with a sterile blade and slide a swab between one occipital pole and cerebellum. It is important to cut off meninges overlying the brain, particularly where it dips between cerebrum and cerebellum. If this is not done, you will rip the front part of the brain from the posterior half as you attempt to remove it. Cut the meninges over the medulla along the dorsal midline.

If it is necessary to sample the brain further for microbiology, do it now before you take the brain out. Cut off a piece of the occipital pole (~ 1 inch cube) with a flamed blade. You do not need to submit half a brain for microbiology. Microbiologists require small pieces of tissue for culture. The pathologist on the other hand needs an intact or nearly intact brain. The sort of handling a brain gets if split longitudinally introduces considerable artifact. One of the few times when it is necessary to cut a brain in half is if organophosphate poisoning is suspected, since half the brain is required for cholinesterase activity.

- If you suspect an ascending infection, including rabies, and cannot send an intact head, please make sure you submit unfixed the most caudal portion of medulla oblongata. This may be the only place where antigen is present.
- If you suspect transmissible spongiform encephalopathy (scrapie or chronic wasting disease), the most critical sample is the obex, which is the portion of medulla oblongata forming the posterior part of the VI ventricle. This should be submitted fixed.

The skull is rested on the occipital condyles and tipped up. The brain reflected dorsally so that attached cranial nerves at the base of the brain can be seen and cut. Begin at the front with the olfactory lobes, cut the optic nerves, and then more posterior nerves along medulla oblongata. The brain will to hang up if you do not sever the large VIII cranial nerve.

For many diseases we must have brainstem to make a diagnosis - please do not leave it in the skull. Handle the brain gently and minimally once out of the vault. Resist the temptation to slice the brain to

take a peek inside. Incising and examining an unfixed brain is rarely informative, and causes considerable distortion during fixation. Gross examination is best done on an intact, properly fixed brain by a pathologist.

Transfer the brain to a 10% formalin solution, ideally at a brain/fixative ratio of 1:10. Once in fixative for a day, ship it to us in a 1:1 ratio of fixative. It won't be completely fixed, but autolysis will be arrested.

Look at the floor of the cranial vault once the brain is out, and check for pus, bilateral symmetry, fractures and tumors. If the postmortem involves feeder cattle, open the tympanic bulla and check for pus. If you suspect malignant catarrhal fever, cut out and submit fixed the pituitary and surrounding soft tissue (carotid rete and trigeminal ganglia) along with the brain. It is important we receive intact brains so that we can take standardized levels for histopathology.